



6<sup>e</sup> workshop medico-sportif.  
Luxembourg, 12-2011

# Painful hip in the athlete. Perspectives of hip arthroscopy.

**Prof. Romain Seil**

Chirurgie  
orthopédique



Centre Hospitalier  
de Luxembourg

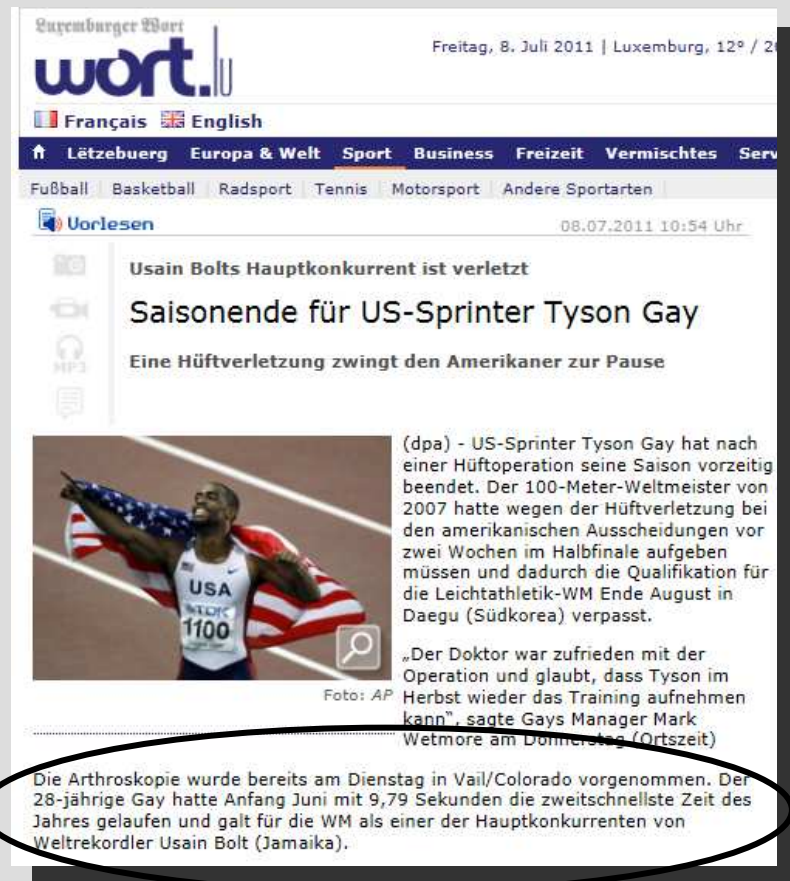Sports Medicine  
Research Laboratory



Centre de Recherche  
Public – Santé,  
Luxembourg



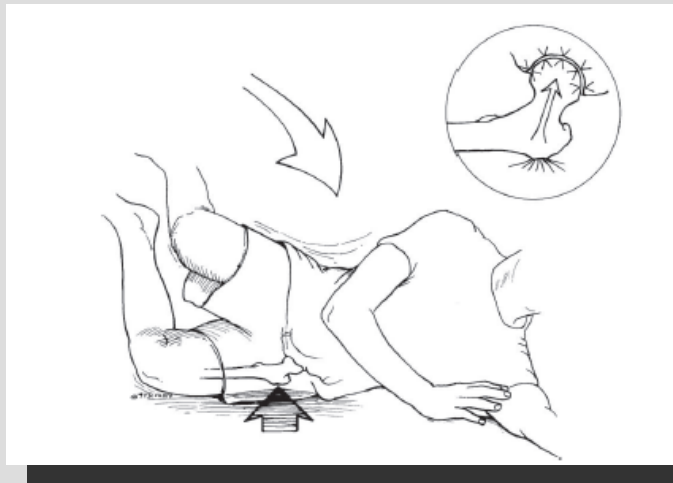
# Hip / groin injuries in athletes



## Sports-school Luxembourg 2008-2010

N	%	
Knee	122	
	25	
Ankle	65	
	14	
Thigh	51	
	11	

# Acute hip / groin injuries in athletes

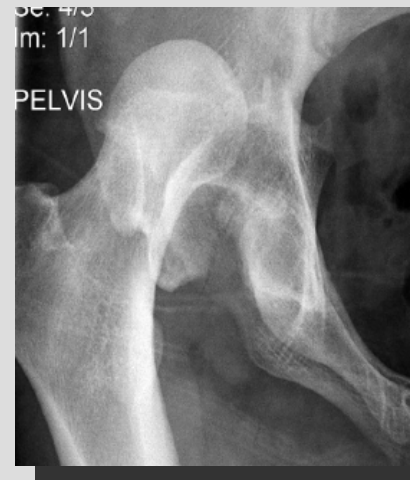

From: Byrd JWT, Op Tech Sports Med 2004

## Femurkopffraktur ohne Hüftluxation bei einem Handballspieler

R. Seil, S. Rupp, T. Hess, T. Hopf

Orthopädische Universitätsklinik und Poliklinik Homburg/Saar  
(Direktor Prof. Dr. med. D. Kohn)



14 professional athletes  
(Am. football, ski, cycling,  
basketball, dancing)

- 100 % labral tears
- 100 % cartilage lesions
- 78 % tears of the lig. teres

Philippon MJ, KSSTA 2009

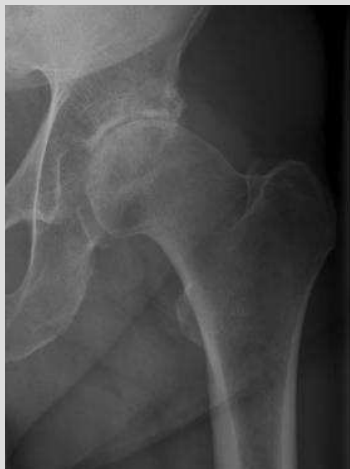# Long-term consequences of sports activity on the hip joint



	N	Hip OA (%)	Knee OA (%)
Football players	57	49	12
Controls	57	26	12

(p<0,05)

Klunder KB, Acta Orthop Scand 1980



	N	Hip OA (%)
Football players	68	13
Controls	136	1,5

Shephard GJ, Br J Sports Med 2003

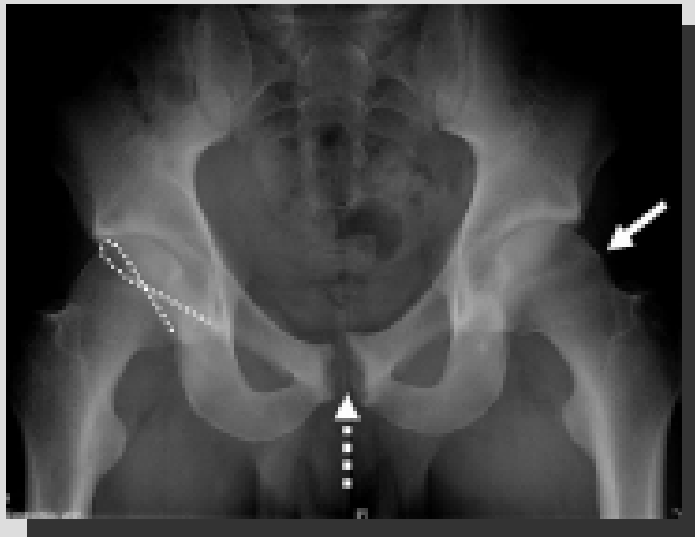

# Hip disorder or pubalgia ?

Treatment of Athletes With Symptomatic Intra-Articular Hip Pathology and Athletic Pubalgia/Sports Hernia: A Case Series

*Arthroscopy: The Journal of Arthroscopic and Related Surgery, Vol 27, No 6 (June), 2011: pp 768-775*

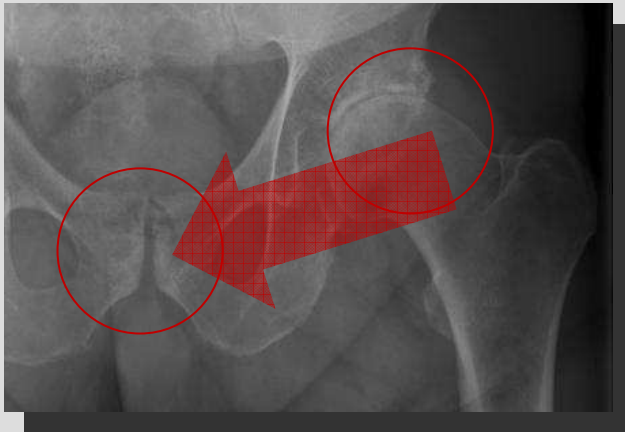
Christopher M. Larson, M.D., Bradley R. Pierce, M.D., and M. Russell Givens, Ph.D.



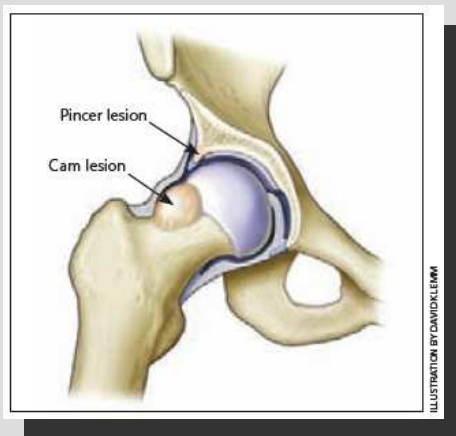- 37 patients with overlap of i.a. hip disorder and athletic « pubalgia/sports hernia »
- Either isolated « pubalgia/sports hernia » surgery or hip arthroscopy
- Or combined surgery
- Isolated management – suboptimal results
- Combined management – 89% unrestricted return to sports



# Hip disorder or pubalgia ?



Influence of femoroacetabular mobility  
on the mobility of the symphysis !



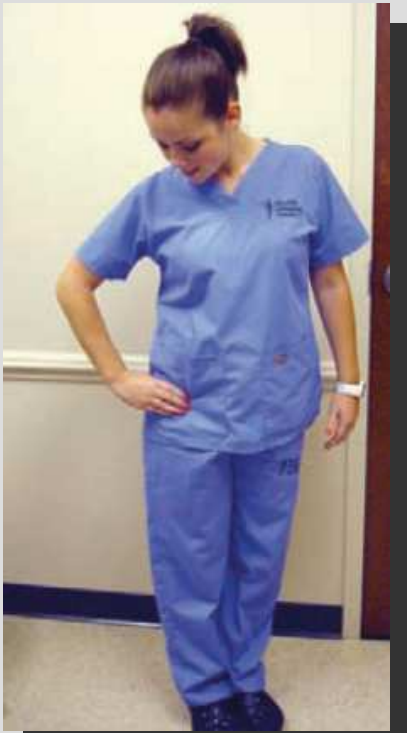From: Kuhlman and Domb 2009

Kelly BT, AOSSM 2011



# Hip pain

« C-sign »



From: Kuhlmann GS & Domb BG; Am Fam Phys 2009

Patients with hip disorder

Compression pain: Groin ( $p < 0.001$ )

Peritrochanteric region

Arnold DR, Keene JS, Blankenbaker DG, Desmet AA.  
Hip pain referral patterns in patients with labral tears: analysis based on intra-articular anesthetic injections, hip arthroscopy, and a new pain "circle" diagram. Phys Sportsmed 2011 Feb;39(1):29-35

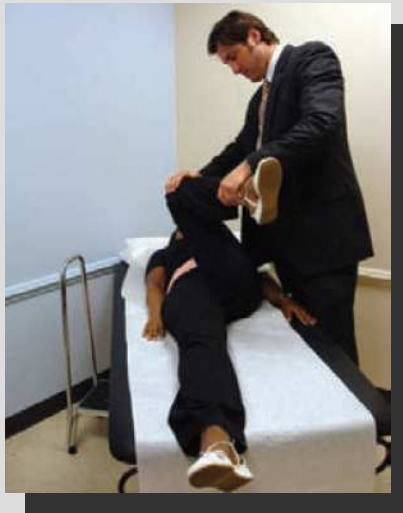




# Clinical examination

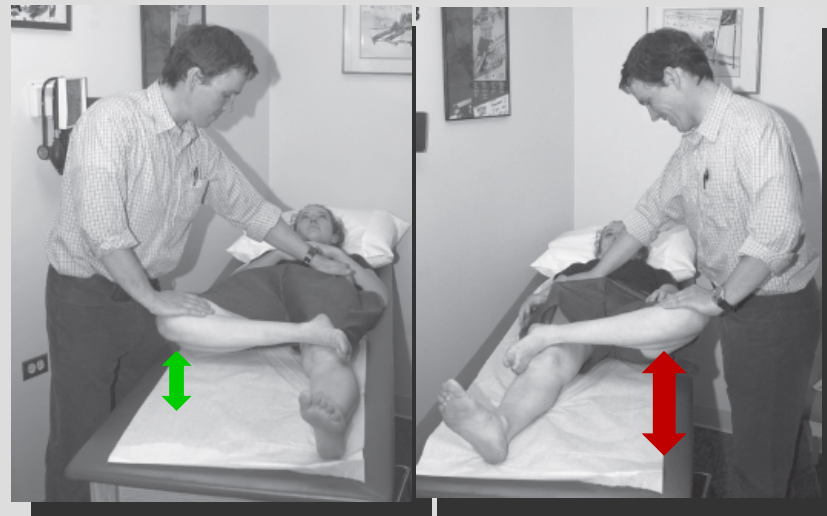
## Reduced mobility ?

Anterior impingement



FADIR Test  
(Flexion – adduction –  
internal rotation)

Posterior impingement

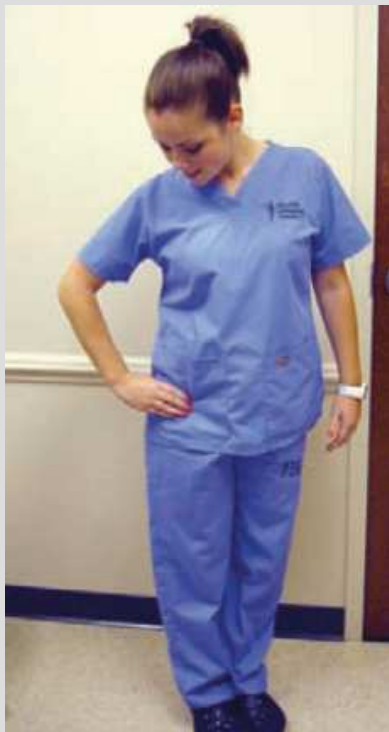

FABER Test  
(Flexion – abduction –  
external rotation)

Leunig M, 2005  
Ito K, 2001 & 2004  
Philippon M, 2006 & 2007



# Differential diagnosis



From: Kuhlmann GS & Domb BG; Am Fam Phys 2009

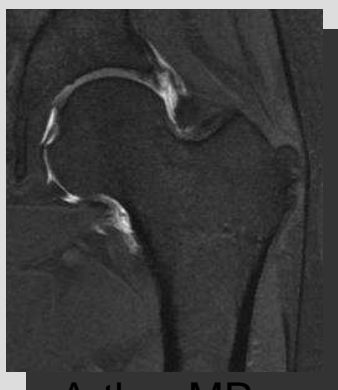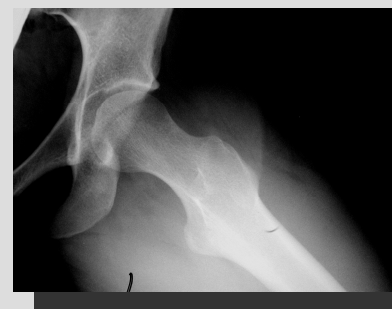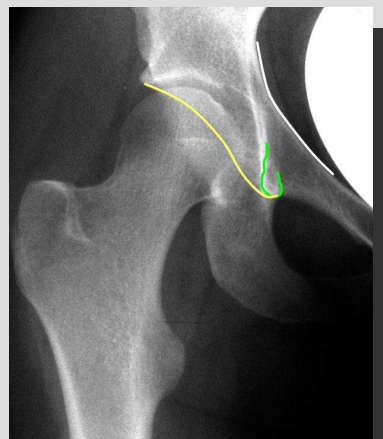
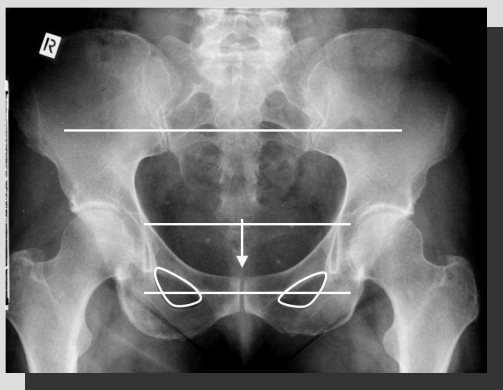
## Hip Pain with Preservation of Joint Space

Primary Labrum	Primary Chondral	Primary Capsule	Extra-articular	Systemic
<p>Trauma</p> <p>Laxity</p> <p>Bony Impingement</p> <p>Dysplasia</p> <p>Degenerative</p>	<p>Lateral impact</p> <p>Subluxation / Dislocation</p> <p>AVN</p> <p>Loose bodies</p> <p>Synovial Chondromatosis</p> <p>Chondrocalcinosis</p> <p>Degeneration</p>	<p>Laxity</p> <p>Adhesive Capsulitis</p> <p>Synovitis / Inflammation</p>	<p>Snapping Hip</p> <p>Internal</p> <p>External</p> <p>Trochanteric Bursitis</p> <p>Ischial Bursitis</p> <p>Psoas Bursitis</p> <p>Osteitis Pubis</p> <p>Sports Hernia</p> <p>Piriformis Syndrome</p> <p>SI Joint</p> <p>Pelvic Obliquity</p> <p>Leg Length Inequality</p> <p>Chronic Tendonitis</p> <p>Hip Flexor</p> <p>Adductor</p> <p>Abductor</p> <p>Gluteus Medius Tear</p> <p>Referred Pain</p> <p>Back</p> <p>Genitourinary</p> <p>Endometriosis</p>	<p>Hormonal</p> <p>Rheumatoid</p> <p>Polyarticular</p> <p>Autoimmune</p> <p>RSD</p> <p>Regional Pain Sx</p>

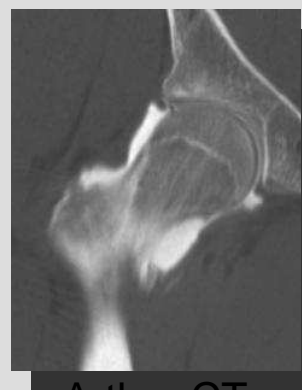From: Kelly BT, Buly RL, HSSJ 2005



# Imaging



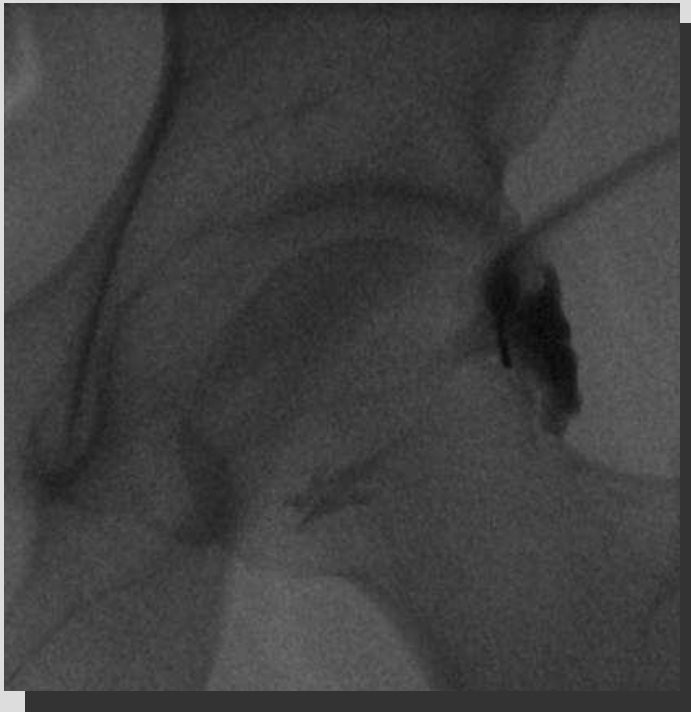
Arthro MR



Arthro CT



# Diagnostic injection

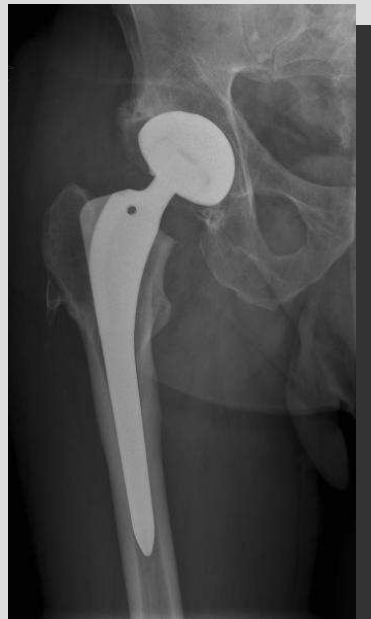
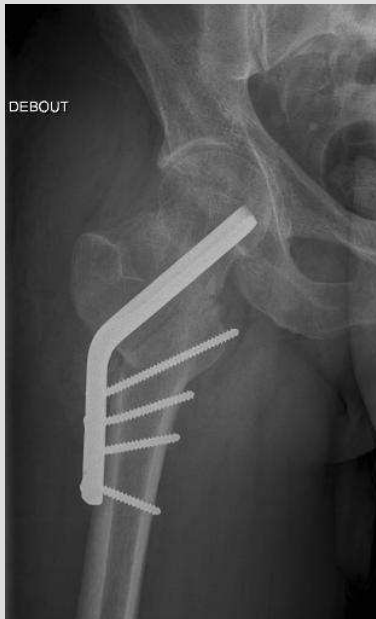
- Radiographic control
- I.a. contrast medium injection
- Local anaesthetics
- (Cortisone)

Byrd JWT, Am J Sports Med 2004



## ...and then ?

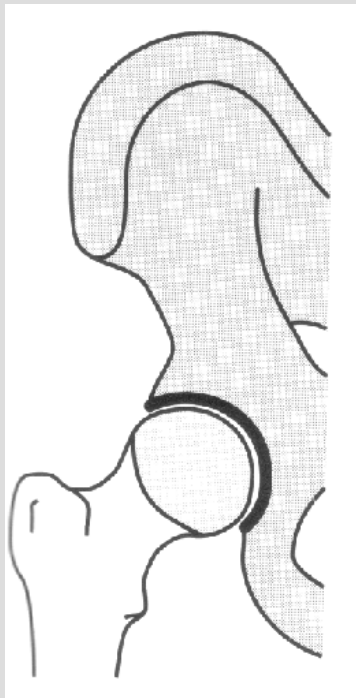


Before the 1990s:

Hardly any therapeutic alternatives besides infiltrations, osteotomies and prosthetic surgery !



# History of hip arthroscopy

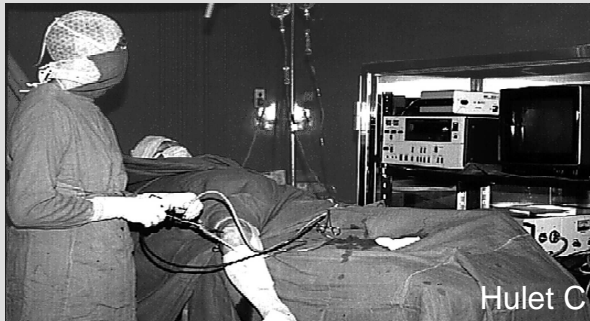


“It is manifestly impossible to insert a needle between the head of the femur and the acetabulum”

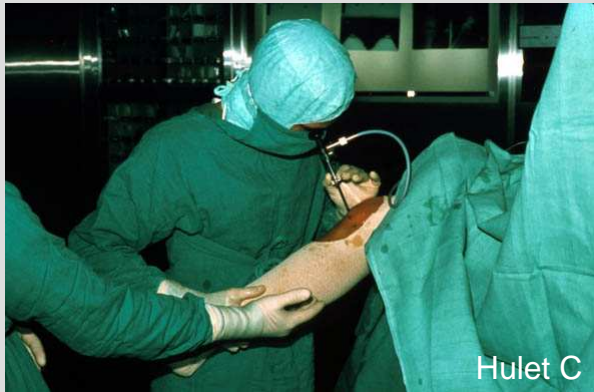
Burman, JBJS 1931



# History of hip arthroscopy

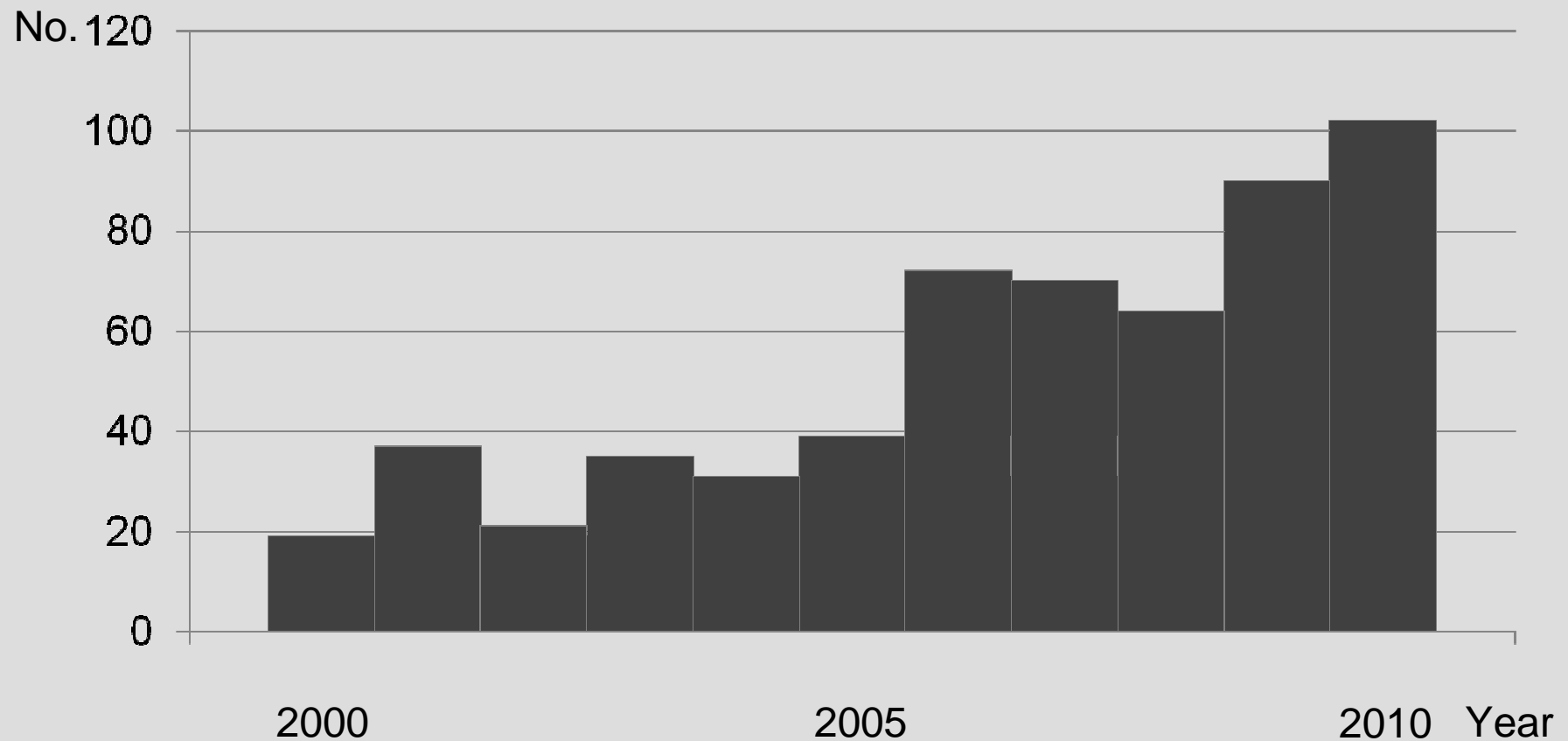


1977-1986: Isolated case reports  
Shifrin, Vakili,  
Eriksson, Gross,  
Holgersson, Rydholm



1987-1999: Indications + technique  
Byrd, Nashville  
Dorfmann & Boyer, Paris  
Glick, San Francisco  
Hempfling, Murnau  
Villar, Cambridge

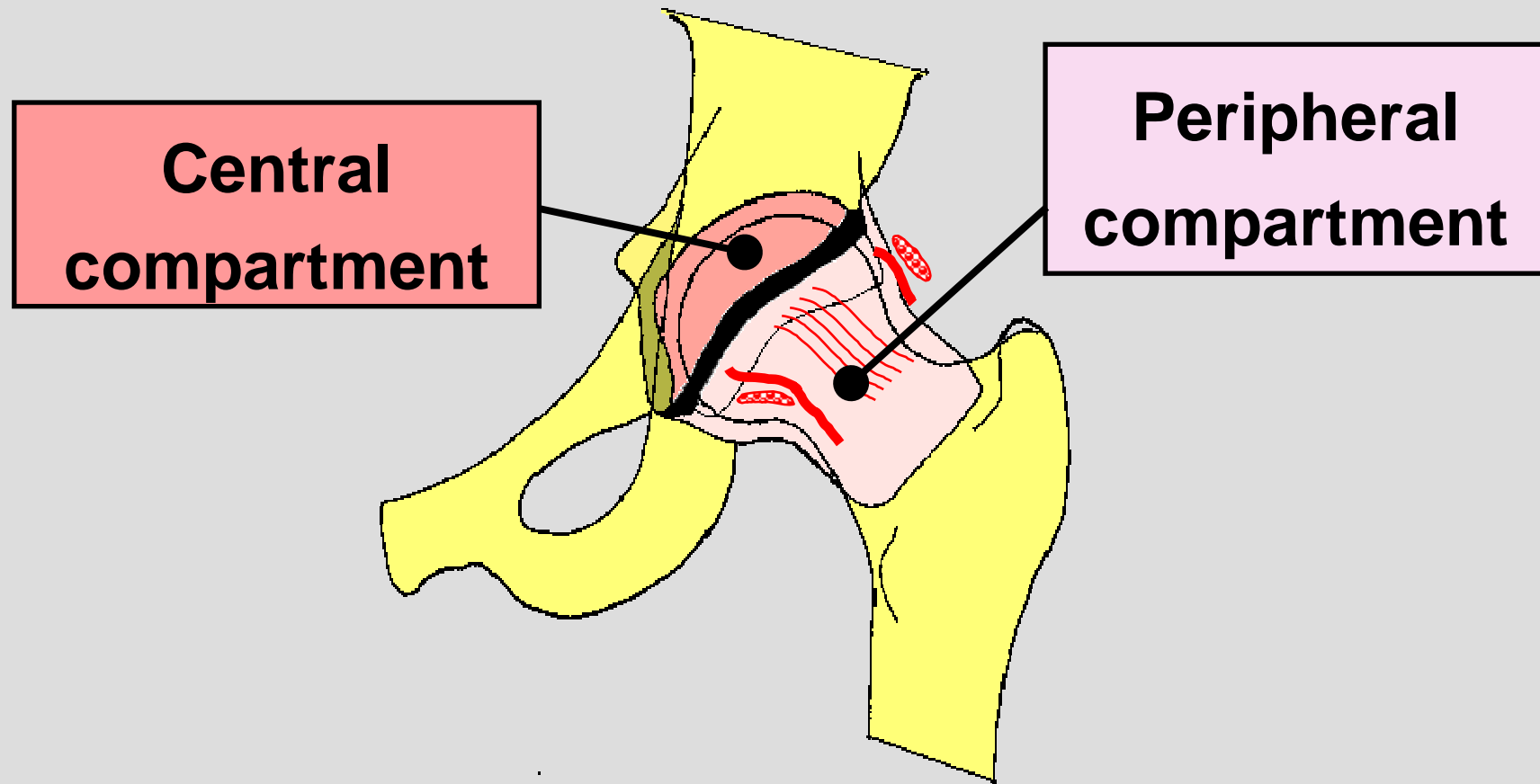
## Pubmed: hip arthroscopy







# Arthroscopic anatomy



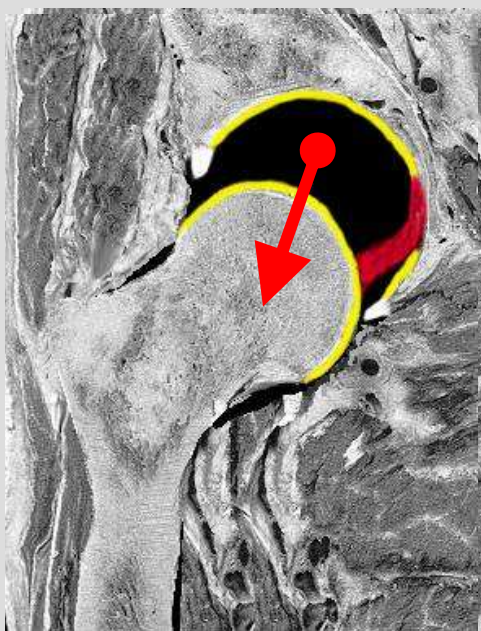Dorfmann and Boyer, Arthroscopy 1999

# Central vs. peripheral compartment

Effects of Traction, Distension, and Joint Position on Distraction of the Hip Joint: An Experimental Study in Cadavers

Michael Dienst, M.D., Romain Seil, M.D., Stefan Gödde, M.D., Michael Brang, M.S., Kurt Becker, M.D., Thomas Georg, and Dieter Kohn, M.D.

2002

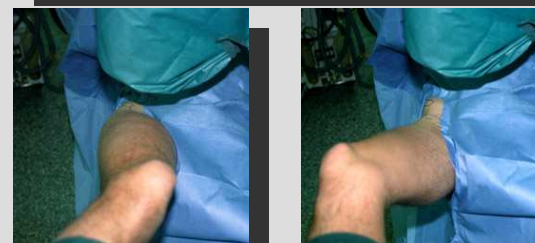
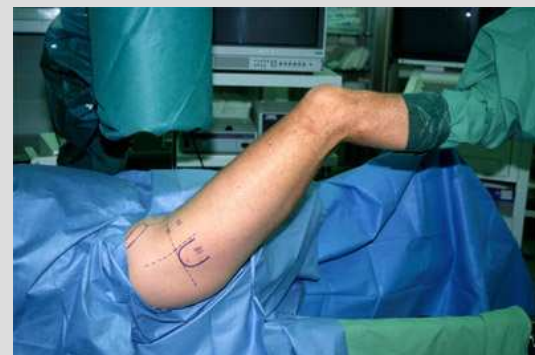
200 – 400 N

Hip Arthroscopy Without Traction: In Vivo Anatomy of the Peripheral Hip Joint Cavity

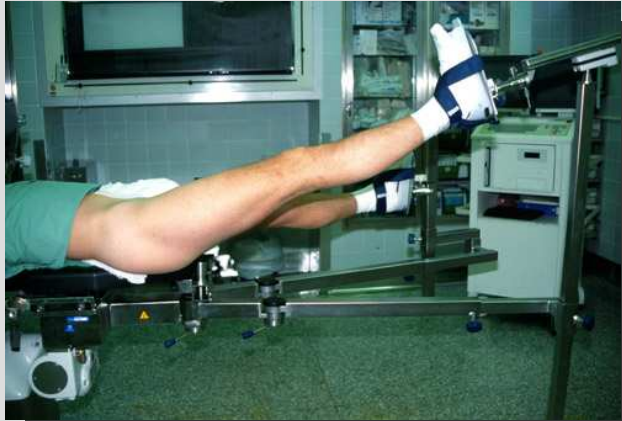Michael Dienst, M.D., Stefan Gödde, M.D., Romain Seil, M.D., Dietrich Hammer, M.D., and Dieter Kohn, M.D.

2001

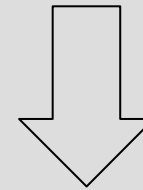




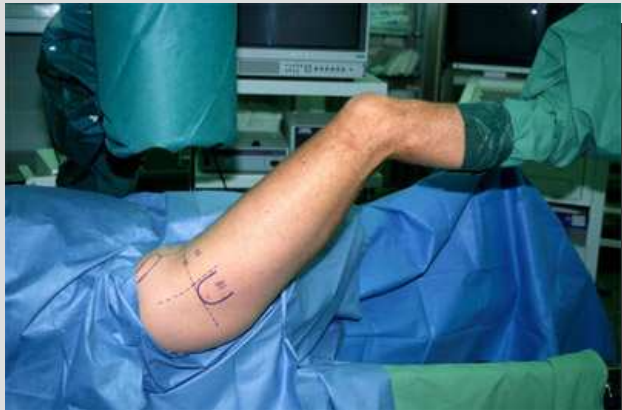# Combined technique



Arthroscopy with traction  
+  
Arthroscopy without traction



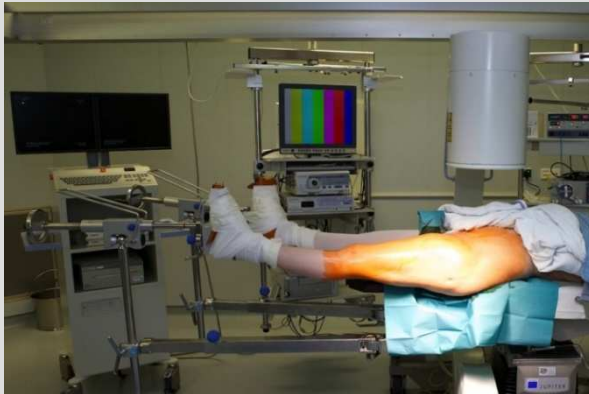
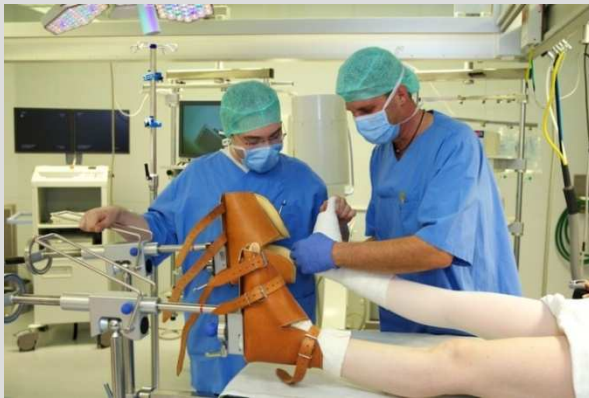Allows for a complete diagnostic  
joint visualisation



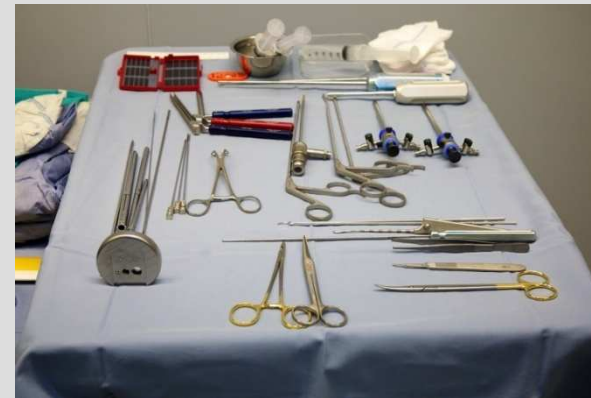

# Patient positioning & equipment

## Traction table



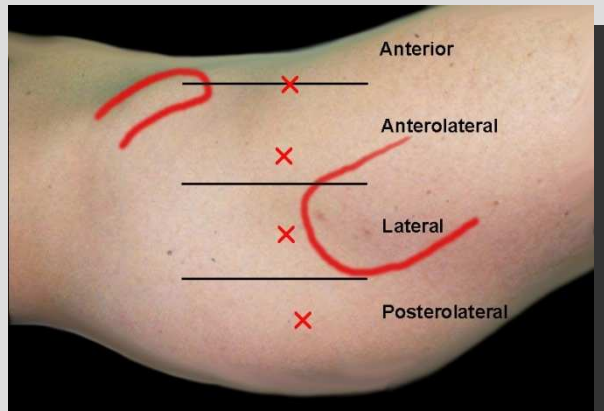
## Specific instruments



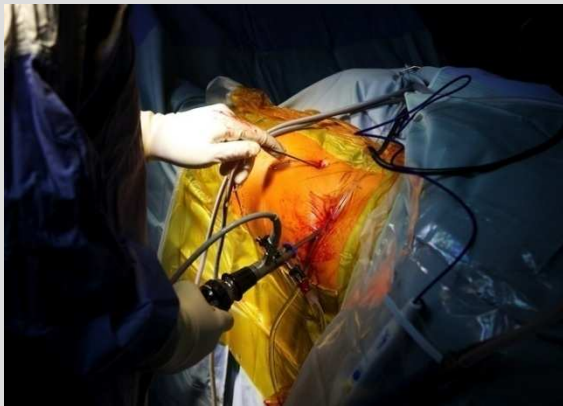
## 30°+ 70° scopes



# Surgery



Courtoisie de M. Dienst, Homburg/Sarre/Allemagne



Injection of contrast medium  
(fluoroscopy)



Needle / nitinol wire



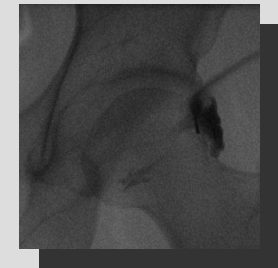
Trocar/Dilators (x3)



Scope / Shaver / Electrocautery/ Halfpipe



Arthroscopic graspers

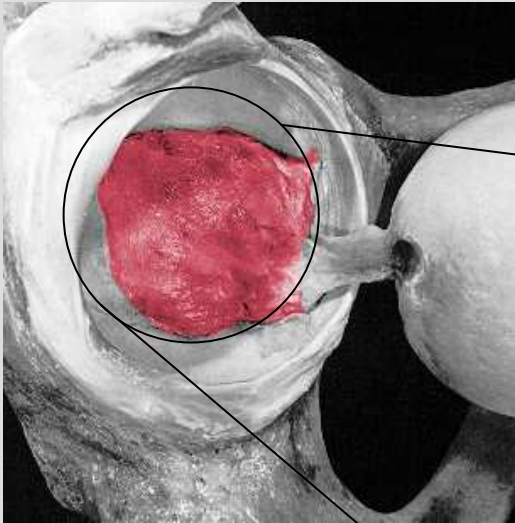




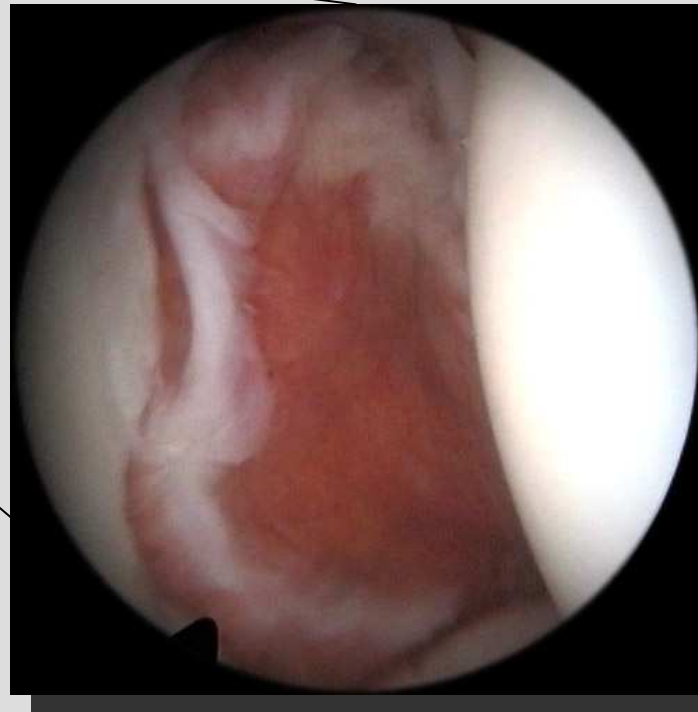

# Arthroscopic anatomy

## Central compartment



Courtesy of M. Dienst, Munich, Germany



Fossa acetabuli

Facies lunata

Labrum

Lig. transversum

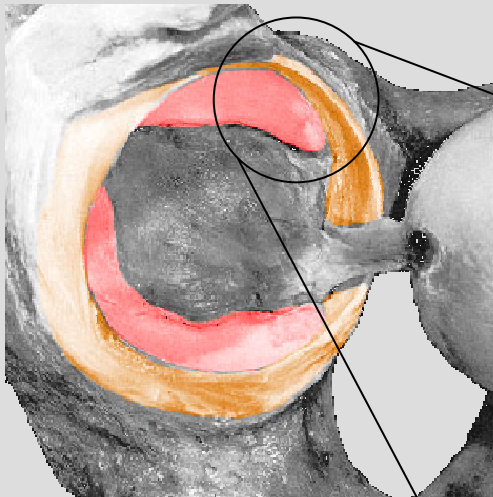
Lig. capitis femoris

Femoral head

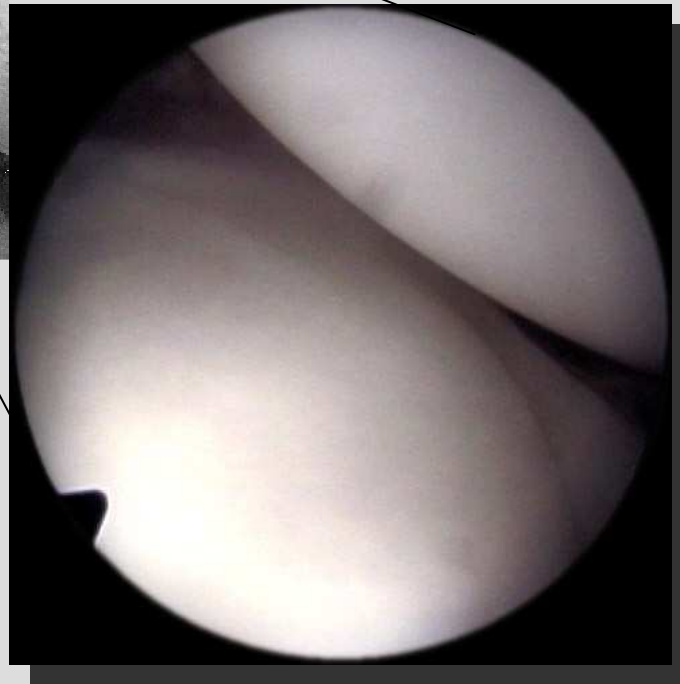

# Arthroscopic anatomy

## Central compartment



Courtesy of M. Dienst, Munich, Germany



Fossa acetabuli

Facies lunata

Labrum

Lig. transversum

Lig. capitis femoris

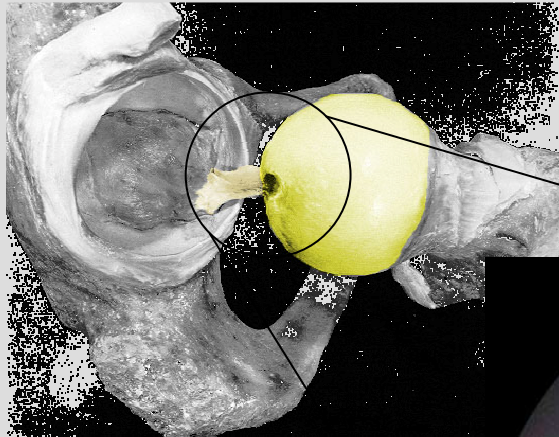
Femoral head



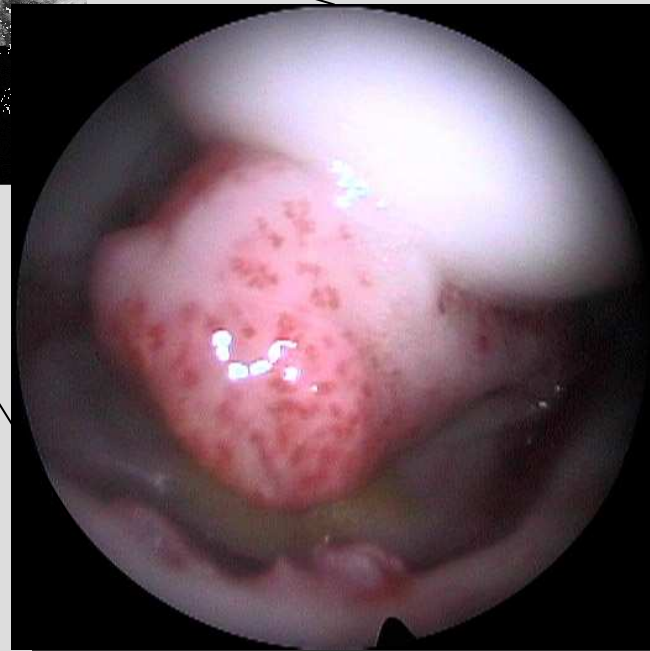


# Arthroscopic anatomy

## Central compartment



Courtesy of M. Dienst, Munich, Germany



Fossa acetabuli

Facies lunata

Labrum

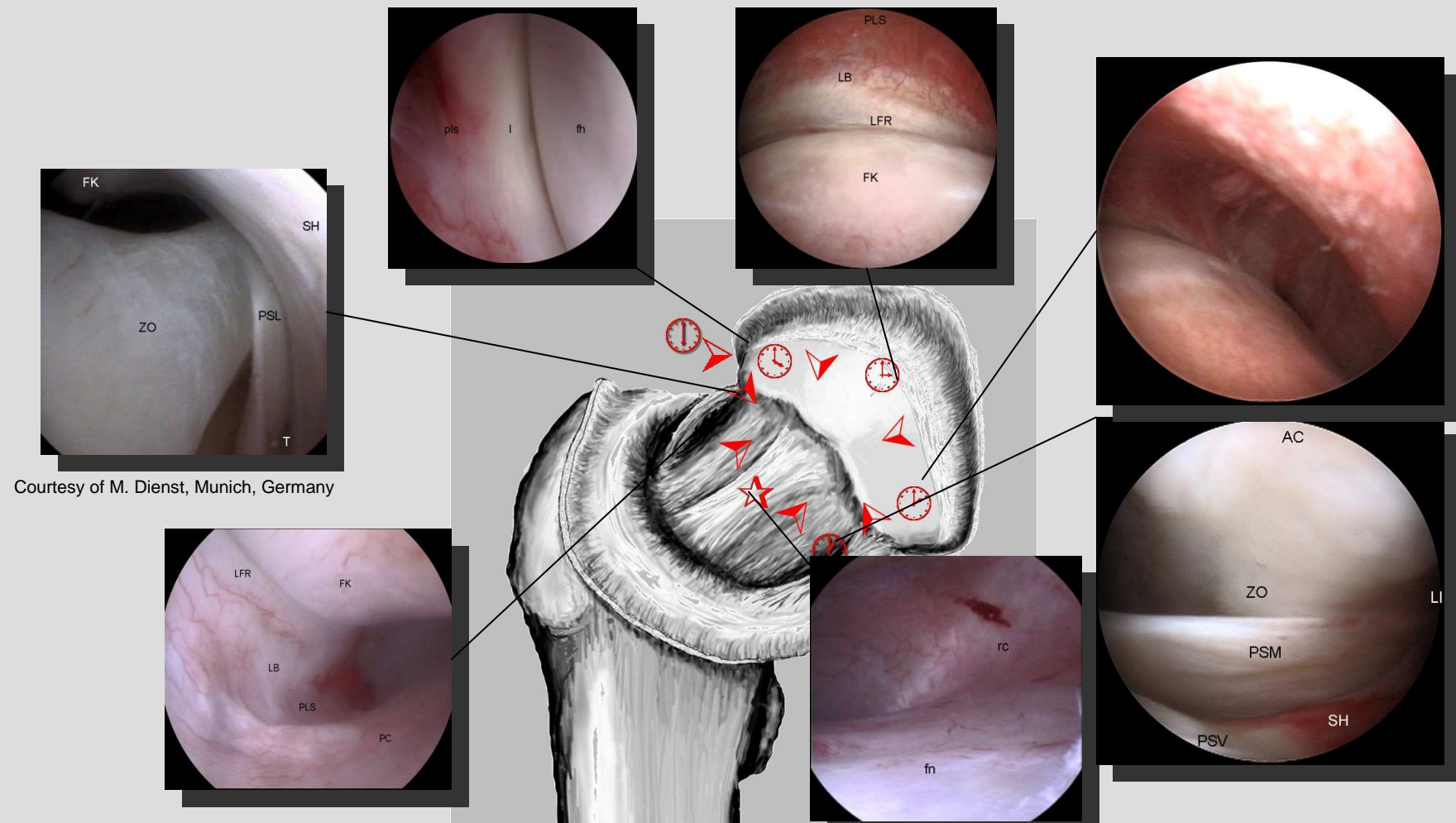
Lig. transversum

Lig. capitis femoris

Femoral head






# Arthroscopic anatomy

## Peripheral compartment



# Differential diagnosis hip pain

## Hip Pain with Preservation of Joint Space

 Primary Labrum	 Primary Chondral	 Primary Capsule	 Extra-articular	 Systemic
Trauma Laxity Bony Impingement Dysplasia Degenerative	Lateral impact Subluxation / Dislocation AVN Loose bodies Synovial Chondromatosis Chondrocalcinosis Degeneration	Laxity Adhesive Capsulitis Synovitis / Inflammation	Snapping Hip Internal External Trochanteric Bursitis Ischial Bursitis Psoas Bursitis Osteitis Pubis Sports Hernia Piriformis Syndrome SI Joint Pelvic Obliquity Leg Length Inequality Chronic Tendonitis Hip Flexor Adductor Abductor Gluteus Medius Tear Referred Pain Back Genitourinary Endometriosis	Hormonal Rheumatoid Polyarticular Autoimmune RSD Regional Pain Sx

From: Kelly BT, Buly RL, HSSJ 2005



# Femoroacetabular impingement

## At risk sports (Hip ABduction/IRO)



### Professional athletes

#### Sports

N

Ice hockey

24

Golf

6

Am. football

5

Football

3

Dancing

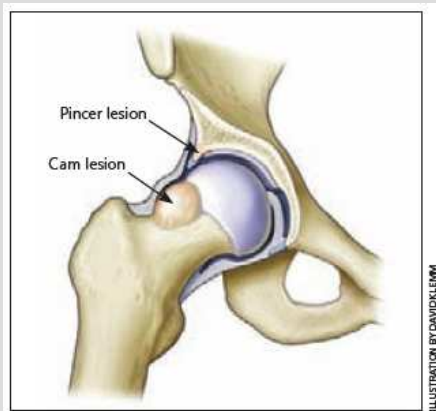Philippon MJ<sup>2</sup>, KSSTA 2007

Baseball

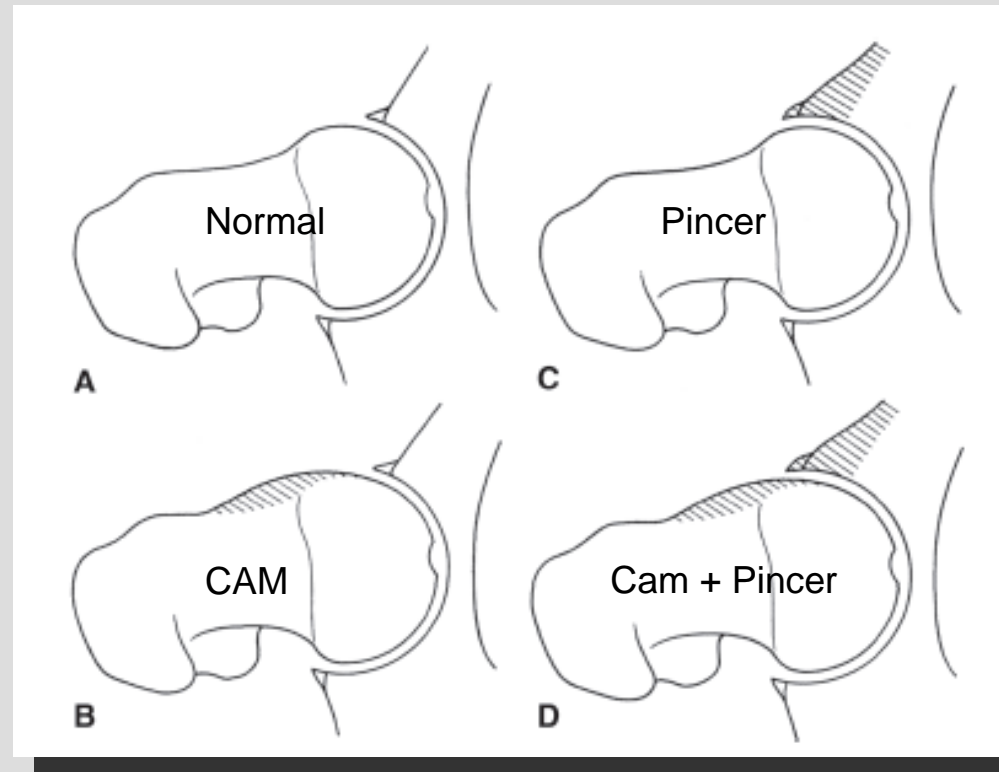




# Femoroacetabular impingement



From: Kuhlman and Domb 2009

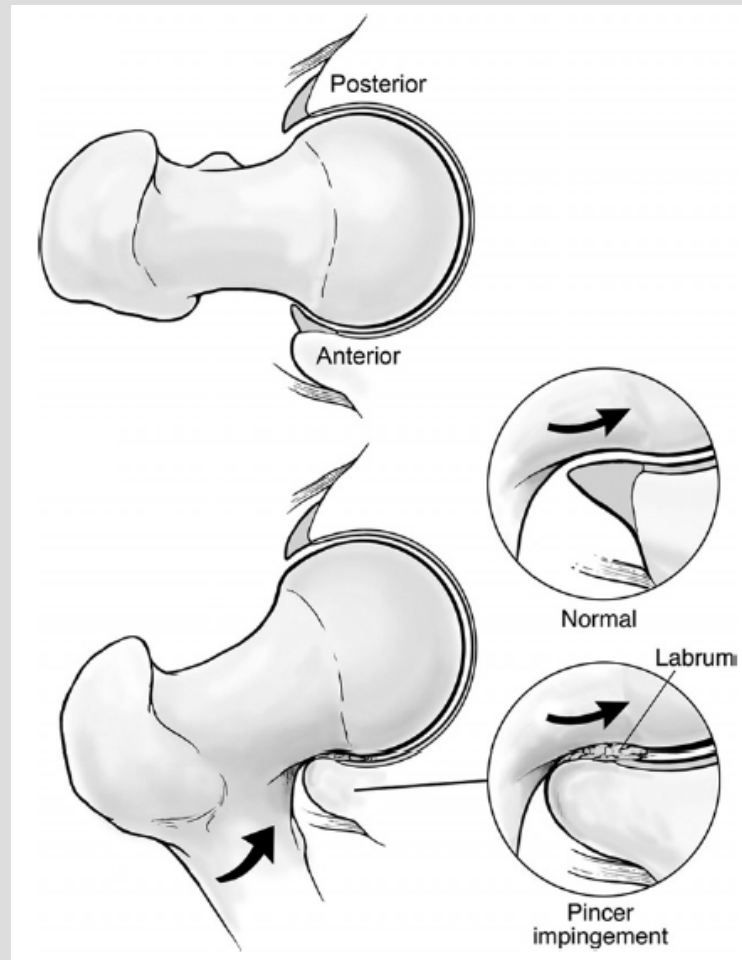


From: Lavigne M, Clin Orthop Rel Res 2004

Ganz R, Parvizi J, Beck M, Leunig M, Nötzli H, Siebenrock KA. Femoroacetabular impingement: A cause for osteoarthritis of the hip. Clin Orthop Rel Res 2003; 417:112-120



# Pincer impingement

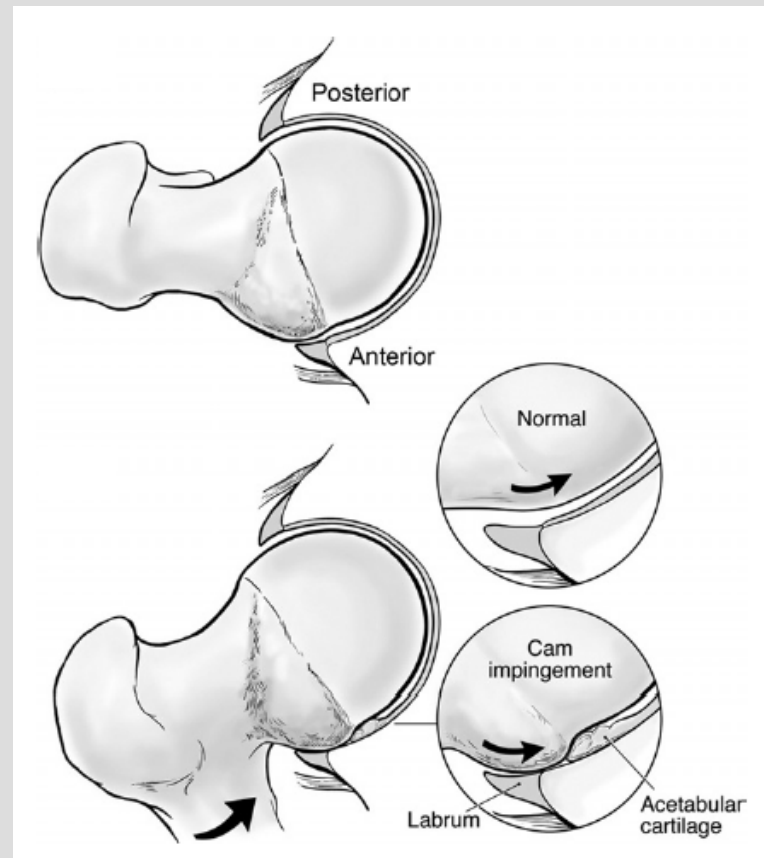


Byrd JWT, Arthroscopy 2011





# CAM impingement



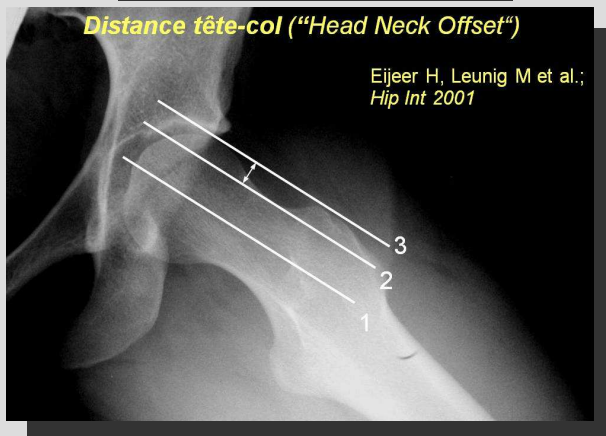
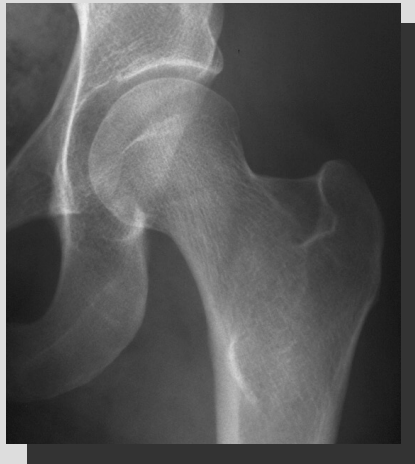Byrd JWT, Arthroscopy 2011



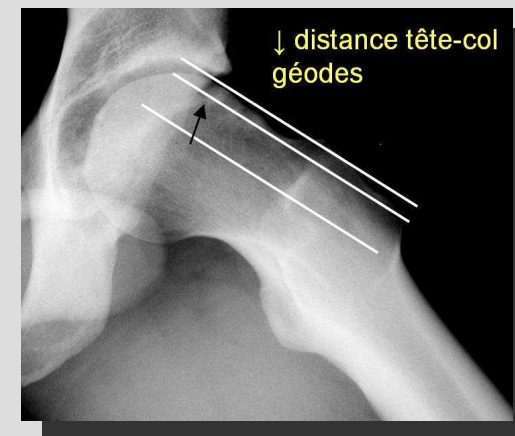
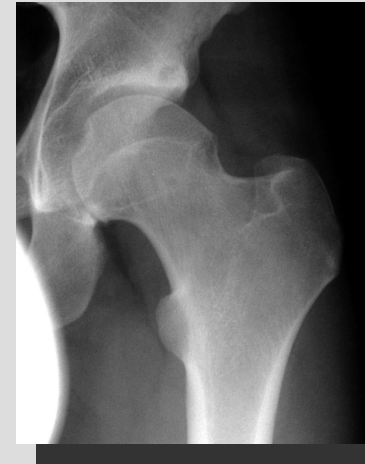

# Femoroacetabular impingement

Normal



« Pistol-grip deformity »



**N8**

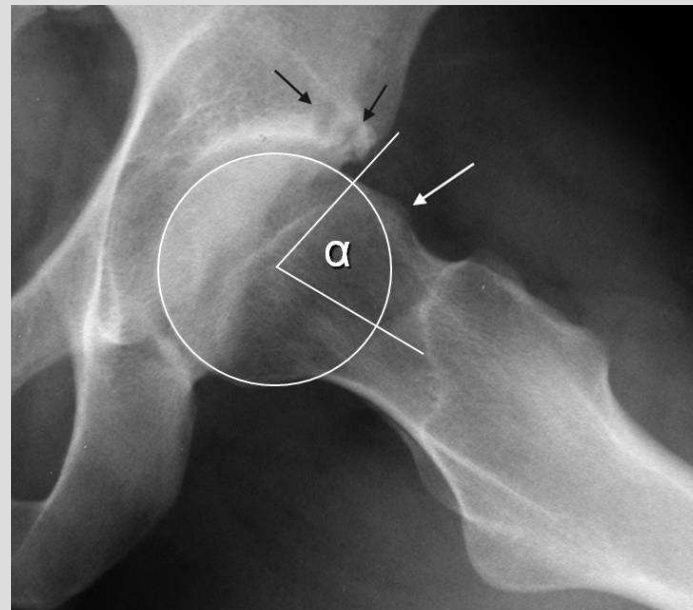
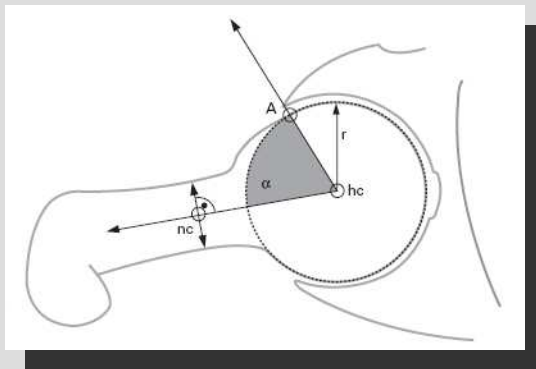
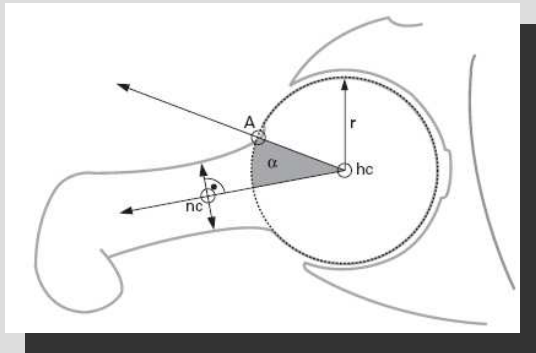
In addition, the head neck offset can be measured in this x-ray-  
Originally described by Eijer and Leunig in the lateral cross table view - you can similarly observe this in the Lauenstein view.  
After drawing a line through the center of the long axis of the femoral head -which is line 1 in this image-  
you draw a line parallel to line 1 - through the anterior aspect of the femoral neck - line 2-  
than a line through the anterior aspect of the head -which is line 3 here-  
and now, the distance between line 2 and 3 can be measured.

Notebook; 15.11.2004



# CAM impingement

$\alpha$  – angle



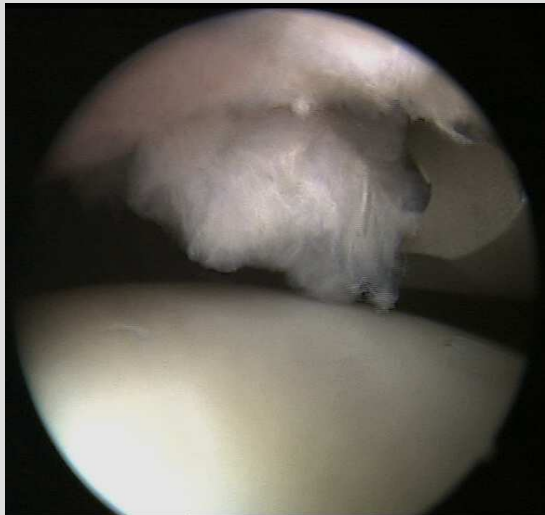
Norm: 42 °

FAI: 74 °

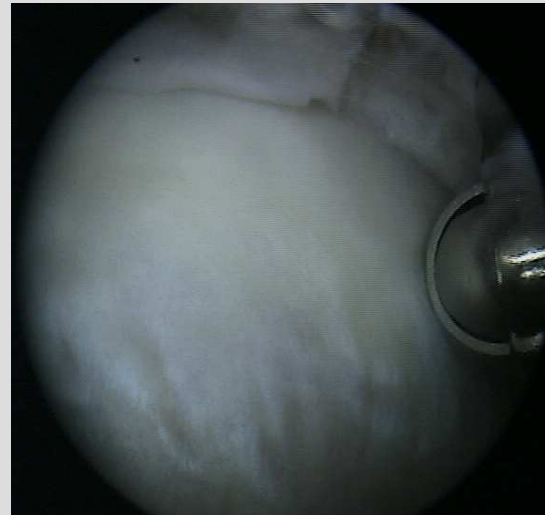
Nötzli HP, JBJS-B, 2002



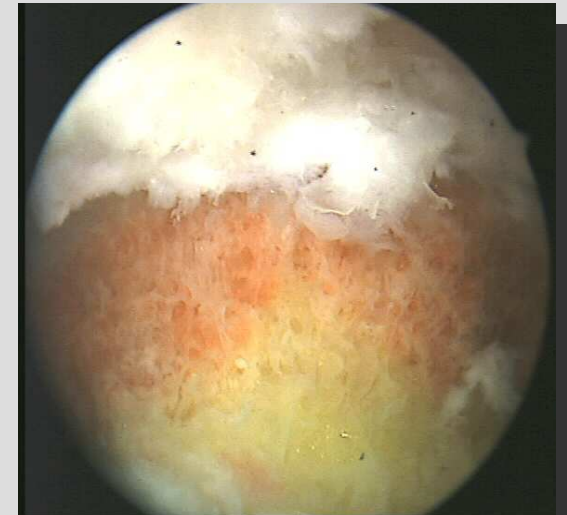# Femoroacetabular impingement



Labral tear



CAM lesion

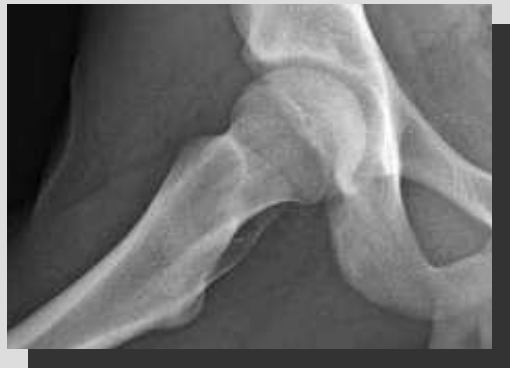

After osteoplasty

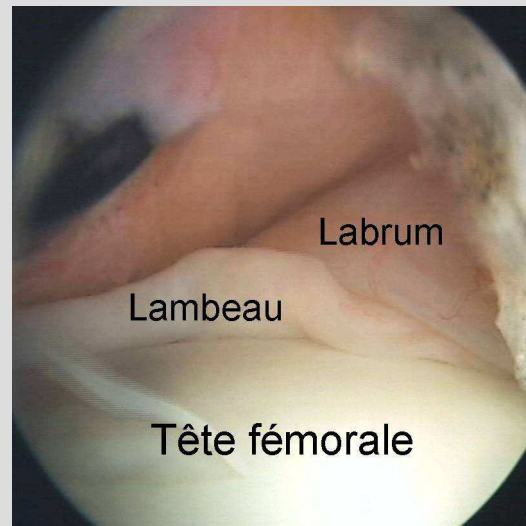
♀ 18 a., ballett



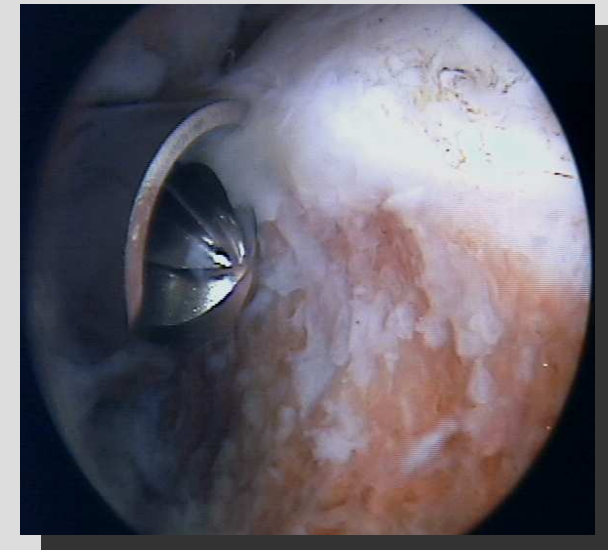# Femoroacetabular impingement



Pathologic  $\alpha$ -angle



Labral tear

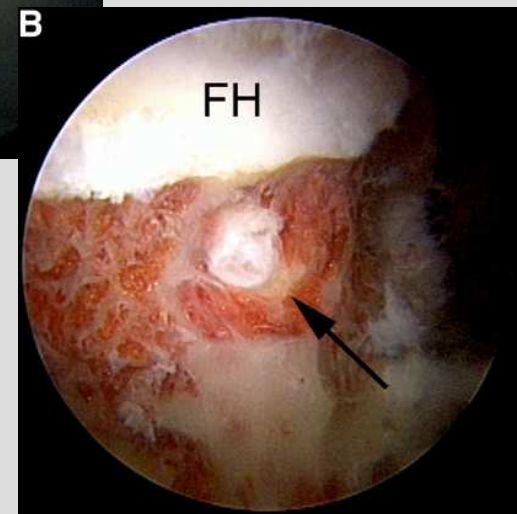
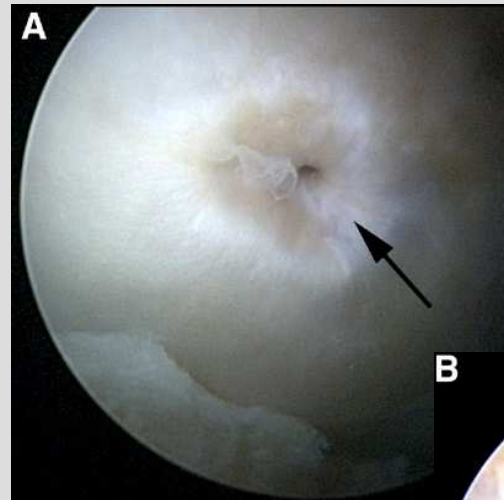
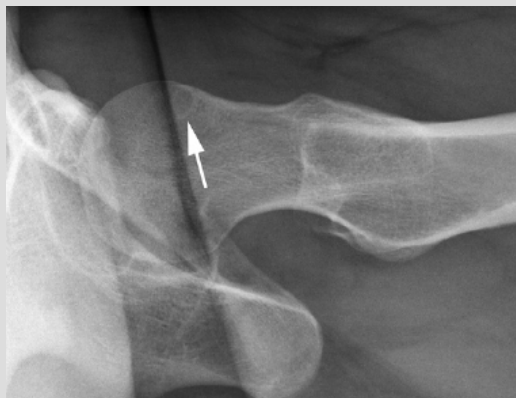
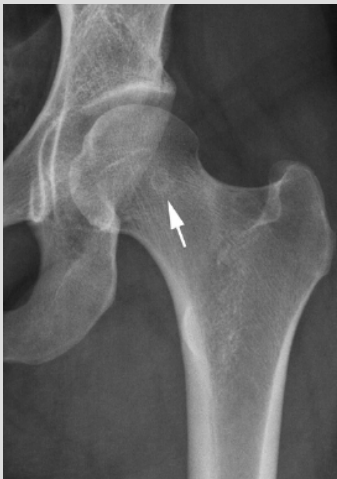
After osteoplasty

18 a., handball



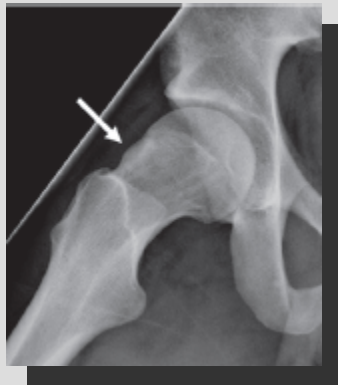
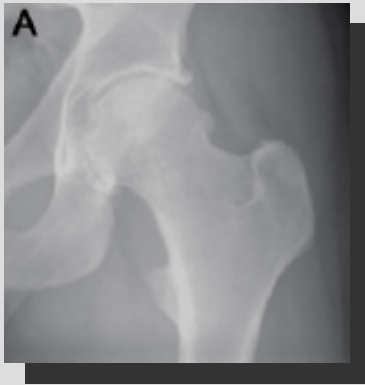# Impingement cysts at head-neck junction



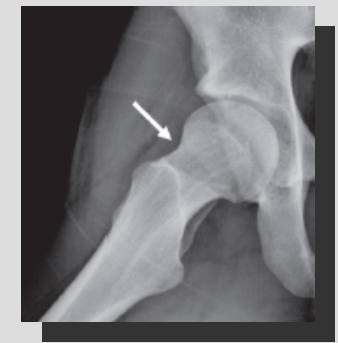
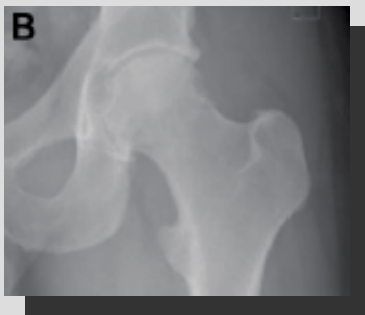Leunig M, Arthroscopy 2011



# Femoroacetabular impingement Results



Retrospective cohort study on 156 patients  
(Evidence level 4)



50 % pain free after 3 months  
75 % after 5 mo.  
95 % after 1 year

Aus: Kelly BT,  
Am J Sports Med 2003

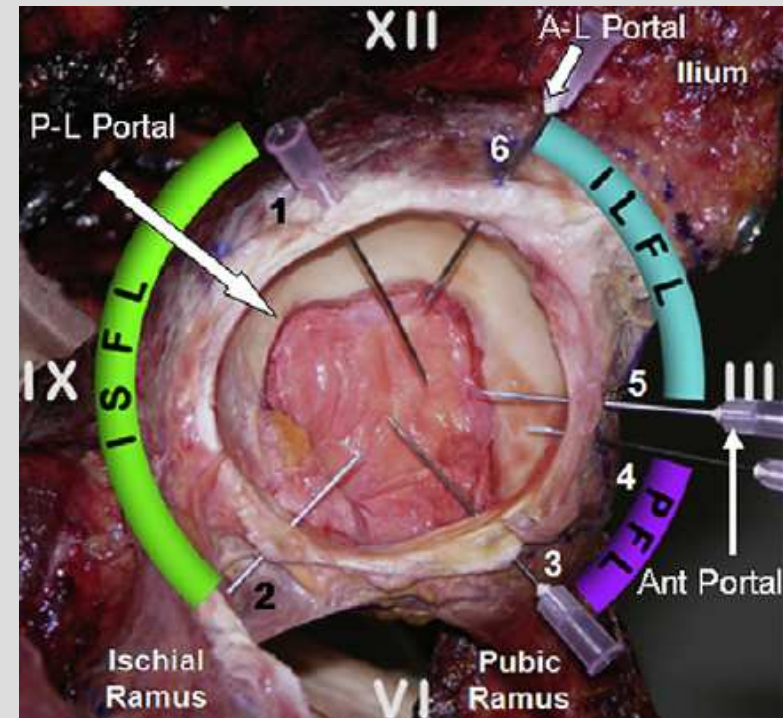
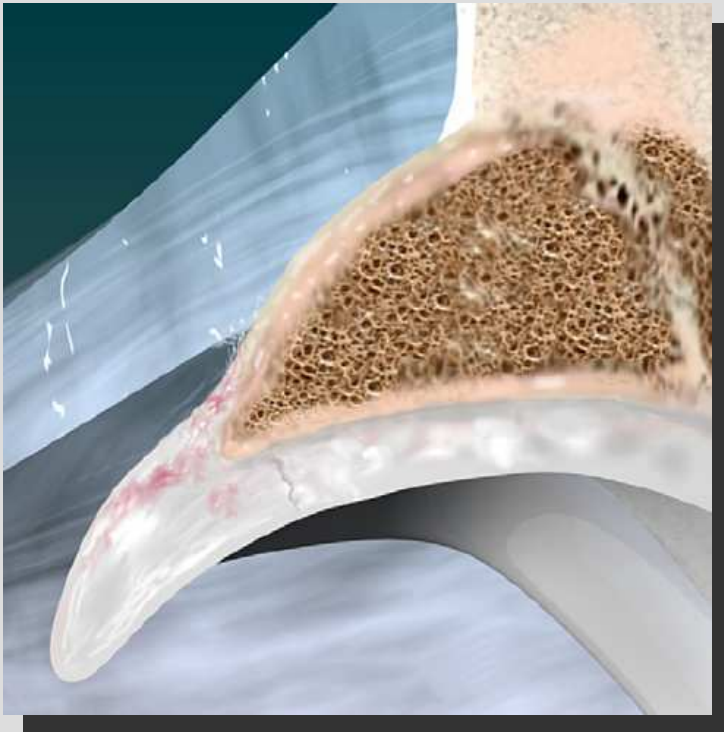
Aus: Larson CM,  
Arthroscopy 2011

Sampson TG, Instr Course Lect 2006





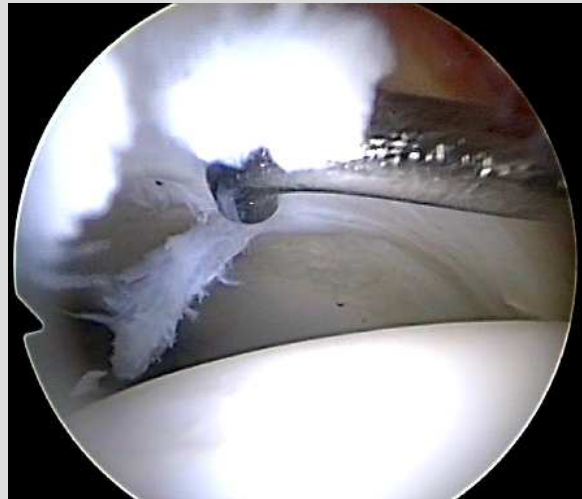
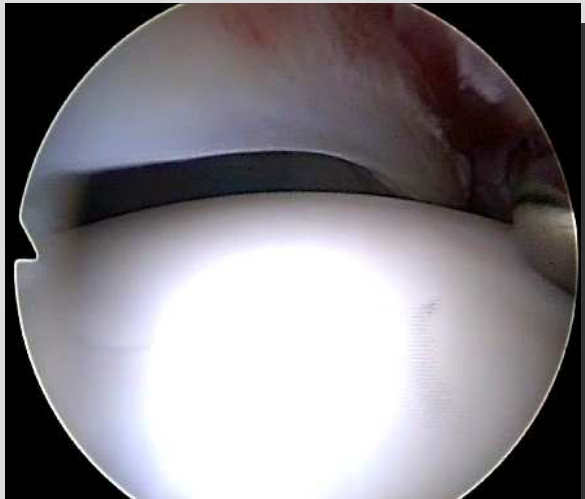# Isolated labral tears



Safran M, Clin Sports Med 2011



# Isolated labral tears



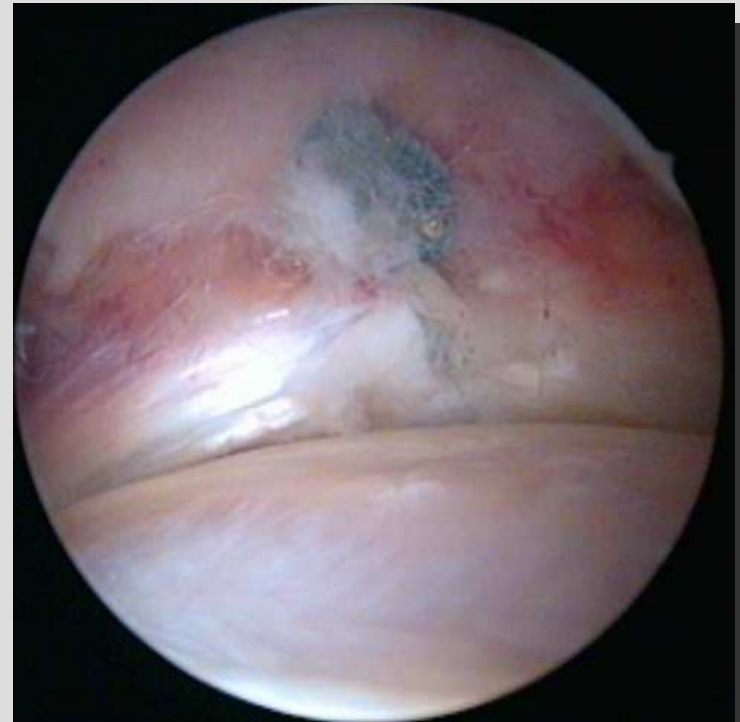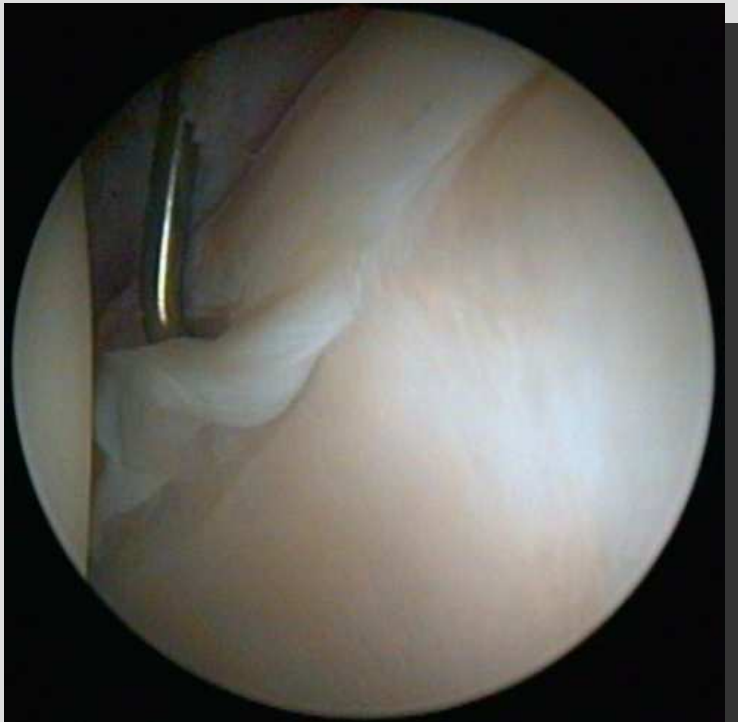Origin:  
50 % degenerative  
20 % traumatic

♀ 19 y., groin pain

Vijay D, Br J Sports Med 2007



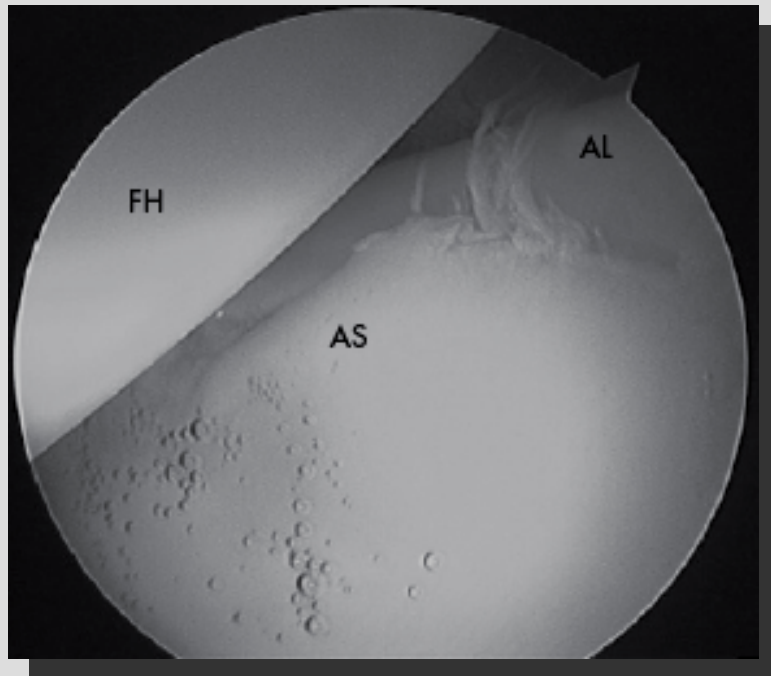
# Isolated labral tears



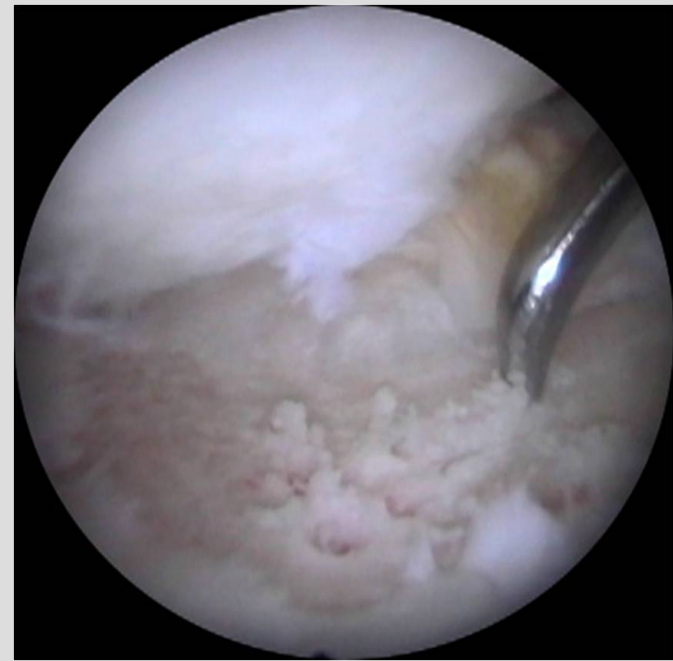♀ 34 y., debridement and refixation



# Cartilage lesions



From: VijayD, Br J Sports Med 2007



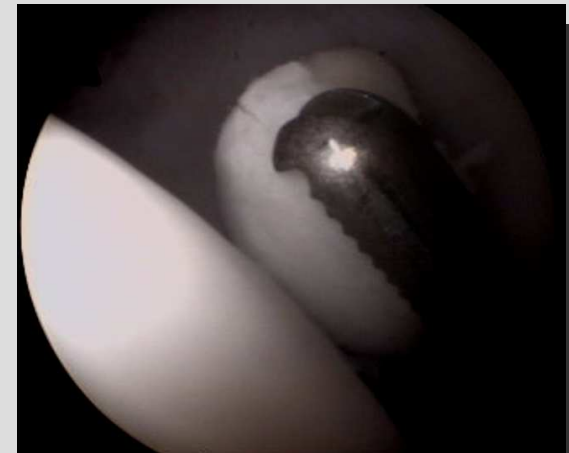
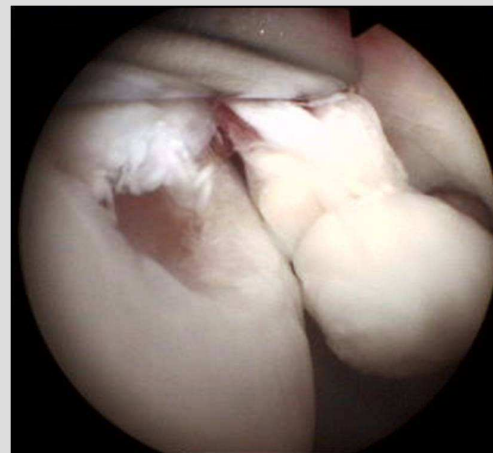
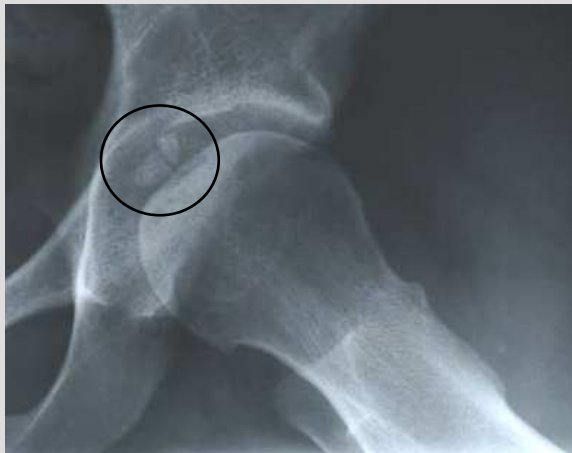

# Loose bodies

## Arthroscopic Treatment of an Avulsion Fracture of the Ligamentum Teres of the Hip in an 18-Year-Old Horse Rider

*Arthroscopy: The Journal of Arthroscopic and Related Surgery, Vol 20, No 6 (July-August, Suppl 1), 2004: pp 64-66*

Matthias Kusma, M.D., Jochen Jung, M.D., Michael Dienst, M.D., Stefan Goedde, M.D.,  
Dieter Kohn, M.D., and Romain Seil, M.D.





## Summary hip pain in sports

- 5 % of acute sports injuries
- Long term: high rate of osteoarthritis
- Complex (differential)diagnosis
- Until recently a hip pathology = end of sports activity



# Summary hip arthroscopy

- Extremely rapid evolution over last decade
- Increased understanding of hip pathologies
- Excellent diagnostic tool, therapeutic options constantly developed
- Minimally invasive surgery; little pain
- Outpatient surgery or short hospital stay
- No compromise of subsequent open surgery
- Low complication rate
- Good results





# Summary hip arthroscopy

Hip arthroscopy needs high-level arthroscopic skills:

- most difficult joint to scope
- careful patient positioning
- precise portal placement
- knowledge of specific arthroscopic anatomy
- specific instruments



[www.medecinedusport-chl.lu](http://www.medecinedusport-chl.lu)

